



# Prospective Comparison of Microsurgical, Tubular-Based Endoscopic, and Endoscopically Assisted Discectomies: Clinical Effectiveness and Complications in Railway Workers

Evgenii Belykh<sup>1,2</sup>, Morgan B. Giers<sup>2</sup>, Mark C. Preul<sup>2</sup>, Nicholas Theodore<sup>2</sup>, Vadim Byvaltsev<sup>1,3</sup>

**OBJECTIVE:** Although endoscopic discectomy is superior to microsurgical discectomy in terms of incision size, postoperative pain, and cosmetic appeal, the effectiveness and indications for endoscopic versus microsurgical discectomy remain active discussion topics. Because of the increasing incidence of discectomies being performed in Russia, further assessment of these techniques is needed. We performed a comparative analysis of 1-year clinical results and complications of microsurgical, tubular-based interlaminar endoscopic, and endoscopically assisted microsurgical discectomies for patients with herniated lumbar disks.

**METHODS:** The patient cohort included 131 patients who were enrolled in a prospective, randomized controlled study and 617 patients for whom data were gathered retrospectively. The quality of life was assessed using the Oswestry Disability Index (version 2.1a) and pain severity was analyzed using the visual analog scale for pain preoperatively, at discharge, and at 3, 6, and 12 months postoperatively.

**RESULTS:** Microsurgical, tubular-based endoscopic, and endoscopically assisted microsurgical discectomies were all effective in relieving acute radicular symptoms. Recurrent disk herniation occurred more frequently after tubular-based endoscopic discectomy than after the other approaches.

**CONCLUSIONS:** Our findings indicate that these 3 surgical techniques are highly effective and have similar clinical results at 1-year follow-up. Although this study points to differences in complications resulting from the 3 techniques, larger prospective studies are needed to more definitively assess possible surgical differences, complications, and outcomes. The endoscopically assisted discectomy technique allows for minimally invasive surgery and offers enhanced visualization of the anatomy that is hidden from view in microscopic procedures.

## INTRODUCTION

Spinal surgery has evolved tremendously since the first work by Mixter and Barr in 1934<sup>1</sup> and since the first successful intervertebral disk operation to resolve diskoradicular conflict. With the introduction of the operating microscope, laminectomy was refined, becoming an open microdiscectomy performed through the interlaminar space, usually with partial bone resection.<sup>2,3</sup> Widely accepted by spine surgeons, microdiscectomy has become the gold standard of treatment for herniated lumbar disks. Rapid technological advancement led to the introduction of minimally invasive tubular endoscopic approaches for herniated disk treatment. Foley and Smith,<sup>4</sup> and later Destandau,<sup>5</sup> published reports of their experiences with minimally invasive endoscopic tubular approaches to herniated lumbar disks as

## Key words

- Discectomy
- Endoscopic assistance
- Endoscopy
- Herniated disk
- Microdiscectomy
- Prospective comparison

## Abbreviations and Acronyms

**EAD:** Endoscopically assisted microsurgical discectomy  
**ED:** Endoscopic discectomy  
**IQR:** Interquartile range  
**K-W:** Kruskal-Wallis test  
**MD:** Microsurgical discectomy  
**ODI:** Oswestry Disability Index  
**VAS:** Visual analog scale

From the <sup>1</sup>Laboratory of Neurosurgery, Irkutsk Scientific Center of Surgery and Traumatology, Irkutsk, Russia; <sup>2</sup>Department of Neurosurgery, Barrow Neurological Institute, St. Joseph's Hospital and Medical Center, Phoenix, Arizona, USA; and <sup>3</sup>Center of Neurosurgery, Irkutsk Railway Clinical Hospital, Irkutsk, Russia

To whom correspondence should be addressed: Vadim Byvaltsev, M.D., Ph.D.  
 [E-mail: [neuropub@dignityhealth.org](mailto:neuropub@dignityhealth.org)]

Citation: *World Neurosurg.* (2016) 90:273-280.  
<http://dx.doi.org/10.1016/j.wneu.2016.02.047>

Journal homepage: [www.WORLDNEUROSURGERY.org](http://www.WORLDNEUROSURGERY.org)

Available online: [www.sciencedirect.com](http://www.sciencedirect.com)

1878-8750/\$ - see front matter © 2016 Elsevier Inc. All rights reserved.

viable alternatives to open surgical techniques. Endoscopic tubular discectomies are perhaps the next step in the trend toward minimally invasive spinal surgery; however, indications for this type of surgery still require more precise definition.<sup>6,7</sup>

Although tubular endoscopic discectomy (ED) is associated with smaller incisions, decreased postoperative pain, and better cosmetic outcomes compared with microsurgical discectomy (MD), its effectiveness, indications, and contraindications remain the subjects of discussion and debate. Few studies have investigated long-term results of quality of life after ED, and even fewer have described positive outcomes; most published studies on ED describe controversial results because of the potential for increased complications.<sup>6-8</sup>

In this study, we conducted a prospective, blinded, and randomized trial to determine 1-year results of MD, tubular-based ED, and endoscopically assisted MD (EAD) in patients with lumbar disk herniation. We also retrospectively reviewed data to assess the complication rates associated with each technique.

## METHODS

### Study Design

From January 2008 to December 2010, a prospective randomized trial and a retrospective registry were conducted for patients with lumbar disk herniation who were candidates for surgical discectomy. The study aimed to assess effectiveness of MDs, tubular-based EDs, and EADs in terms of improved quality of life and pain reduction in the first postoperative year. The early and late complication rates of patients were determined by performing a retrospective assessment of operative dictations, and by gathering follow-up data from patients not included in the prospective randomized study.

This study was approved by the hospital ethics committee, and written informed consent was obtained from all patients.

### Inclusion Criteria

All patients in this study underwent neurologic and instrumental examinations that included plain and lateral lumbar radiographs, lumbar magnetic resonance imaging (MRI), and electro-neuromyography. Patients were included in this study if they met the following criteria:

- Age between 18 and 70 years old
- Conservative treatment of more than 3 months' duration was ineffective
- Experienced frequent low back pain and sciatica recurrence ( $\geq 3$  times per year)
- Displayed evidence of root neurologic symptoms
- L3/L4, L4/L5, or L5/S1 intervertebral disk herniation was evident on MRI or computed tomography
- Able to sign a voluntary informed consent form for participation in the study, surgery, and data collection

Patients were excluded from study if they had undergone previous spinal surgery or had multilevel herniation, degenerative

stenosis of the lumbar spine, vertebral segment instability, or severe somatic disease.

### Patient Groups

For the prospective portion of the study, patients were randomly assigned to 1 of the 3 surgical discectomy technique groups (MD, ED, or EAD) using Statistica 8 (StatSoft Inc., Tulsa, Oklahoma, USA). Patients were blinded to the type of surgical technique. The same surgical team, consisting of 3 neurosurgeons who were experienced in MD, ED, and EAD, performed all operative procedures. Standard surgical instrument sets were used in all cases. The patient population in this study consisted of railway workers with physically demanding jobs that regularly require heavy lifting, pushing, and pulling. Postoperatively, most patients were discharged to the corporate rehabilitation center. The inpatient rehabilitation program was typically 11–14 days and may have included therapeutic medications, massage, physical therapy, reflexotherapy, traditional Eastern medicine, and dietary management.

### Surgical Intervention Techniques

General operative descriptions are given below for each type of procedure because the procedures may vary slightly among surgeons. All patients underwent intravenous general anesthesia with artificial pulmonary ventilation. Patients were placed in a prone position with positioning pads under the shoulders and superior iliac crests. The affected level was verified by intraoperative C-arm fluoroscopy.

**MD Technique.** A 3-cm longitudinal incision was made at the midline, above the spinous processes of 2 adjacent vertebrae. The aponeurosis was opened with an arciform incision. The paraspinal muscles were dissected from the spinous processes and from adjacent vertebrae arches in a subperiosteal layer. The Caspar Micro Lumbar Discectomy retractor (Aesculap, Tuttlingen, Germany) was inserted into the operative field and dilated to the appropriate size. The operation took place under 4–12 $\times$  magnification of the operative microscope, and Aesculap microsurgical spinal instruments were used in all cases. An interlaminar approach was used, and the ligamentum flavum was excised. When necessary, adjacent vertebral arches were partially resected. At this point, the nerve root and the dural sac served as landmarks. After dissection of adhesions, the microdiscectomy was performed. Nerve root pulsation and its free displacement indicated adequate discectomy. Hemostasis was obtained by bipolar coagulation and, in some cases, application of Surgicel (Ethicon Inc., Somerville, New Jersey, USA).

**Tubular-Based ED Technique.** The ED technique and instruments (Karl Storz, Tuttlingen, Germany) in this study followed the manner described by Destandau.<sup>5</sup> A 2.0- to 2.5-cm longitudinal incision was made 1–2 cm lateral to the midline. The aponeurosis was then exposed and cut longitudinally with a scalpel. Next, the operating tube with obturator was introduced through the muscle incision, toward the interlaminar space. The obturator was removed and hemostasis was achieved by bipolar coagulation. The endoscope was fastened in the working channel of the tube, and the prolapsed disk was then approached under endoscopic

control. The overhanging fragments of soft tissue were removed and the ligamentum flavum was excised and resected. If necessary, the lamina was partially resected to improve the approach to the lateral parts of the spinal canal and nerve root. After the root had been identified, it was retracted with a nerve protector that had been integrated into the working insert of the operative tube. The posterior longitudinal ligament was dissected if it obscured the herniated lumbar disk, and the herniated disk was removed. The spinal canal was then inspected for any residual disk fragments, the operating tube was removed, and hemostasis was secured.

**EAD Technique.** The EAD technique was performed along the same guidelines as shown above for the MD procedures. The microscope and microsurgical spinal instruments used in the MD procedures were supplemented in EAD cases with the endoscopic console and spinal endoscopes (Karl Storz). The final stages of the procedure (ie, removal of herniated disk, revision of the ventral space of the vertebral canal, removal of free and displaced fragments of sequestered disk, and hemostasis) were performed under visualization of 0° and 30° endoscopes in addition to microsurgical visualization.

**All Techniques.** In all surgeries, incisions were closed in separate layers. Aggressive total discectomy or removal of all mass of the lumbar disk was never needed; only the sequestered, herniated part of the lumbar disk was removed. Specific information about surgical approaches, time of operation, and estimated blood loss were recorded in the operative charts. The patients were instructed to ambulate within 3 days of the operation and were advised to follow an orthopedic regimen that included the use of a rigid orthopedic belt for 1 month postoperatively.

### Outcome Measurements

All patients were assessed when they checked in for surgery, at the time of hospital discharge, and at follow-up appointments 3, 6, and 12 months after surgery. Patients completed a questionnaire at each follow-up appointment yielding their Oswestry Disability Index (ODI) score (ODI version 2.1a was translated into Russian for this study).<sup>9</sup> The ODI score was considered the primary outcome. Pain severity was evaluated using the visual analog scale (VAS).<sup>10</sup>

Occurrence of intraoperative and postoperative complications was assessed in a separate cohort by retrospectively reviewing patient charts and operative dictations. The following complications were recorded and analyzed: wrong level approach, dura mater injury, nerve root injury, instrument breakage, postoperative hematoma, infection, spondylodiskitis, transient partial urination disturbance, neurologic deterioration, herniation recurrence, and segmental instability. Conversions from ED to EAD were also recorded and assessed.

### Statistical Analysis

Statistical analysis was performed using Statistica. The necessary statistical power of the study and the number of cases in each group were calculated, and the ODI score was considered the main indicator of functional outcome. A minimum of 37 cases was needed in each group to achieve 80% statistical power, with

$P < 0.05$  as the 2-tailed level of significance indicating achievement of the minimum clinically significant 10-point difference in ODI score (standard deviation = 15).<sup>11,12</sup>

Significance was tested using the following nonparametric statistical tests: the Kruskal-Wallis (K-W) test for multiple independent groups, Mann-Whitney U test for 2 independent groups, Wilcoxon signed-rank test for dependent samples,  $\chi^2$  test for binominal data, and  $\chi^2$  Fisher exact test for small numbers of patients. The quantitative attributes are presented as the median and the interquartile range (IQR; lower quartile, upper quartile).

All data were analyzed using the initial group assignment, disregarding any surgical conversions. The initial group assignment was maintained to attribute the surgical complication resulting from the ED portion of the surgery to that group. The Wilcoxon analysis did not exclude patients with missing data on follow-up examination. Cases with missing data were assumed to be random and therefore were not considered to influence the comparison results.

## RESULTS

### Patient Characteristics

Between January 2008 and December 2010, 131 patients treated at the Irkutsk Railway Clinical Hospital met the inclusion criteria and were enrolled in the prospective randomized study. The patients' preoperative characteristics were comparable in all 3 groups of the prospective portion of this study (Table 1). Most patients (80%) were between the ages of 31 and 56 years. In all treatment groups, men prevailed. This was in contrast with the worldwide trend<sup>13</sup> and was attributed to the predominance of railway workers, most of whom are men, in our study. Overall, 95% of disk herniations were at the L4/L5 and L5/S1 levels.

Four patients randomized to the ED group experienced technical difficulties during surgery, necessitating introduction of the microscope and converting the operation from an ED procedure to an EAD procedure. These 4 patients were assessed in the ED group. Additional data were retrospectively gathered on 617 patients who underwent ED, EAD, or MD. The median, minimum, and maximum periods of follow-up observation for the retrospective cohort were 2 years, 3 months, and 6 years, respectively. Between the prospective and retrospective cohort, information was gathered on 738 patients who underwent surgery for lumbar disk herniation.

### Surgical Treatment

All patients underwent discectomy using an ED, MD, or EAD technique. Partial laminotomy or foraminotomy was performed for adequate decompression of nervous structures in 7 of 39 (18%) EAD cases, 14 of 48 (29%) MD cases, and 9 of 44 (20%) ED cases (Table 2). Total surgical time averaged 1.5 hours in all groups, with no significant difference observed among groups. The estimated blood loss was around 50 mL in almost all operations. The average incision size in ED cases was smaller than in MD cases ( $P = 0.01$ ) (Table 2).

The patients in the ED group spent the fewest days at the hospital (median, 10 days; IQR, 8.5,10; range, 6–11), compared with MD patients (median, 10 days; IQR 9,11; range, 5–19) and

**Table 1.** Initial Patient Characteristics by Treatment Group

Variable	Microsurgical Diskectomy (n = 48)	Endoscopic Diskectomy (n = 44)	Endoscopically Assisted Microsurgical Diskectomy (n = 39)	P Value*
Mean age, years, median (IQR)	39.5 (37,49)	41 (32,49)	39 (36,48)	0.65
Female, number (%)	21 (44)	16 (36)	12 (31)	0.45
Herniation level, number (%)				
L3/L4	2 (4)	2 (5)	2 (5)	
L4/L5	18 (38)	21 (48)	15 (38)	
L5/S1	28 (58)	21 (48)	22 (56)	
Mean ODI, median (IQR)	50 (30,65)	40 (30,57)	40 (24,58)	0.10
VAS, median (IQR)	72 (49,91)	69 (52,89)	73 (43,91)	0.95

IQR, interquartile range; ODI, Oswestry Disability Index; VAS, visual analog scale.  
\*P values indicate significance among the 3 groups by Kruskal-Wallis test.

EAD patients (median, 10 days; IQR, 9,11; range, 7–19) (P by K-W test [ $P_{K-W}$ ] = 0.03).

### Outcomes

At discharge, ODI scores indicated highly significant improvement in patients' quality of life in all groups ( $P < 0.01$ ) (Figure 1). At 3-month follow-up, patients' functional status was further improved from the discharge status. In all groups, ODI scores improved 3–6 months after the operation. Intergroup comparison showed no difference in the patients' ODI scores across groups 3, 6, and 12 months after diskectomy ( $P_{K-W} = 0.08$ ,  $P_{K-W} = 0.18$ , and  $P_{K-W} = 0.33$ , respectively).

VAS scores (Figure 2) indicated considerable pain relief immediately after surgery ( $P < 0.01$ ) and between discharge and the 3-month follow-up ( $P < 0.01$ ), remaining low thereafter. Although there was significantly lower pain in the ED group than in the EAD and MD groups immediately postoperatively ( $P_{K-W} = 0.03$ ), there was no difference between pain scores at any later

time point (3 months,  $P_{K-W} = 0.14$ ; 6 months,  $P_{K-W} = 0.92$ ; 12 months,  $P_{K-W} = 0.61$ ).

### Complications

Complications from all 738 assessed cases were categorized as intraoperative, postoperative common surgical complication, and postoperative complication specific to diskectomy; they were then organized by disease and operation type (Table 3). Intraoperative complications included iatrogenic dura mater injury (with or without cerebrospinal fluid leak), nerve root injury, and tool breakage (breakage of rongeurs and its fragment abandonment in disk cavity). An additional complication, which occurred in 5 cases, was an initial approach performed at the wrong spinal segment despite radiologic assistance. The difference in the intraoperative complications among the 3 groups was not significant.

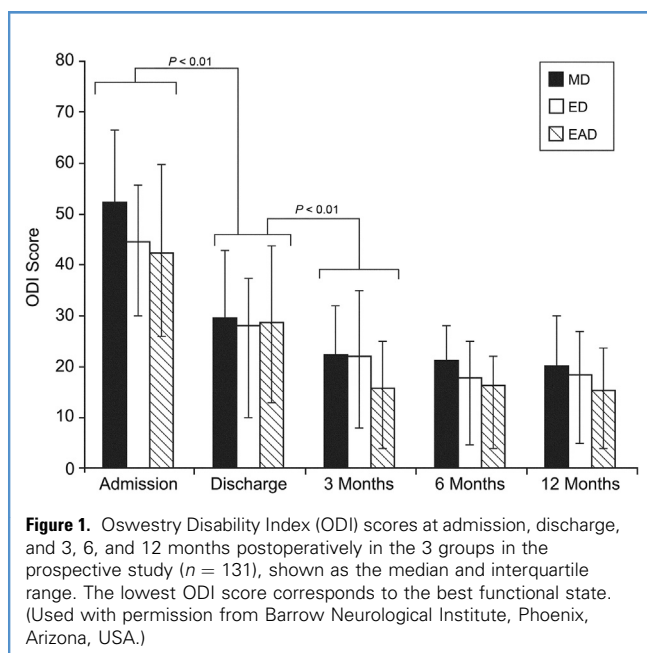
There were no cases of venous thrombosis or pulmonary embolism. Cases of postoperative wound infection and hypodermic or intermuscular hematomas were successfully treated conservatively.

**Table 2.** Operative Characteristics by Treatment Group

Variable	Microsurgical Diskectomy (n = 48)	Endoscopic Diskectomy (n = 44)	Endoscopically Assisted Microsurgical Diskectomy (n = 39)	P Value*
Hernia removal				0.2
Interlaminar, number (%)	34 (71)	35 (80)	32 (82)	
Interlaminar with partial bone decompression, number (%)	14 (29)	9 (20)	7 (18)	
Mean surgical time, minutes, median (IQR)	105 (70,125)	90 (75,115)	103 (90, 115)	0.3
Mean blood loss, mL, median (IQR)	50 (30,50)	40 (30,50)	50 (30,50)	0.5
Mean incision size, mm, median (IQR)	30 (30,30)	25 (20,25)	30 (25,30)	0.01

IQR, interquartile range.  
\*P values indicate significance among the 3 groups by the Kruskal-Wallis test.





Two patients developed spondylodiskitis, which improved after a course of antibiotic therapy. Four patients had partial urinary disturbances during the postoperative period, which later resolved.

During the follow-up period, 31/738 patients (4.2%) had pain recurrence as a result of recurrent herniation at the level of operation. Of those, 3 reherniations in the ED group, 2 in the MD group, and 1 in the EAD group occurred within the first 6 months after the surgery. Another 31/738 (4.2%) patients developed

vertebral segment instability. In 30/738 other cases (4.1%), neurologic deterioration or pain occurred after a pain-free interval; postoperative fibrosis was likely the cause.

When all 738 cases were considered, significantly more recurrent herniations occurred after ED than after MD ( $P = 0.04$ ). The number of recurrent hernias in the EAD and MD groups tended toward a significant difference ( $P = 0.06$ ). In contrast, development of postoperative instability in the operated segment was noted more often in the MD group than in the ED group ( $P = 0.03$ ).

## DISCUSSION

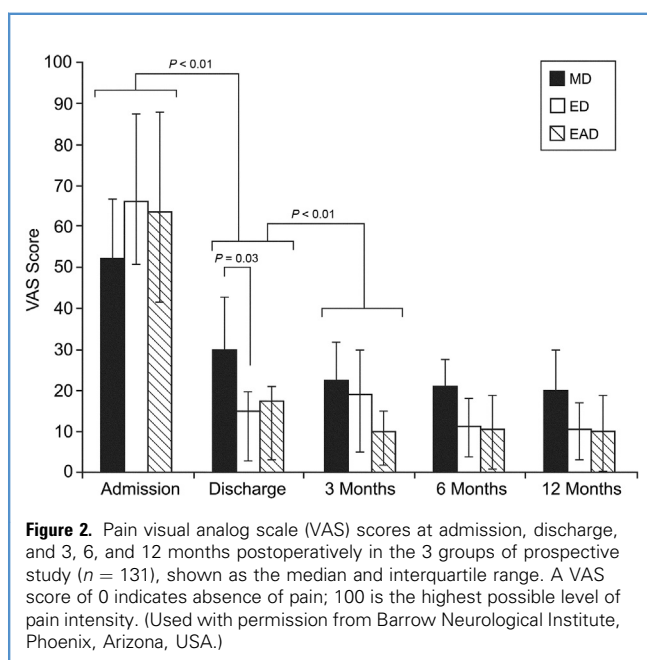
This study reflects the experience and treatment outcomes of lumbar discectomies among ED, MD, and EAD techniques in the Irkutsk Region of eastern Siberia. Most of the patients in this study are railway workers and compose a distinctive, fairly homogeneous patient population. The department of health care at the Joint Stock Company Russian Railways includes 112 private, company-owned outpatient clinics and rehabilitation centers, and 123 inpatient hospitals across Russia. The company's health care program includes neurosurgical care and has specific recommended procedures for treatment and rehabilitation programs.

The primary advantages of minimally invasive techniques such as tubular ED are decreased postoperative pain, improved cosmetic appearance of the surgical site, and accelerated functional rehabilitation. Patients are believed to recover more quickly because the postoperative pain decreases as a result of minimized intraoperative trauma, leading to better postoperative outcomes. Many previous studies indicate that the primary advantages of endoscopic techniques are cosmetic, and that decreased pain after ED is better only in the immediate postoperative period. These reports<sup>6,7,14</sup> show no significant differences in functional outcome between tubular ED and MD techniques. The long-term outcomes of ED procedures are still the subject of debate because of complication rates, pain outcomes, and recurrences.<sup>6,14</sup>

The results of our study showed improved quality of life and decreased pain intensity 1 year after discectomy across the ED, MD, and EAD groups, with the prolonged effectiveness of treatment not differing among groups; however, the pain intensity during the early postoperative period was least in the ED group, most likely because of decreased trauma to the soft tissue associated with the ED approach.

Across all groups, the patients' quality of life and pain intensity were improved most during the 3–6 months postoperative period. This may be explained by the postoperative rehabilitation experience, in which quality of life is gradually restored as pain decreases. According to the results of our study, these scores did not show statistically significant changes once patients reached the 12-month postoperative mark. Therefore, the optimal time to assess the surgical results may be the period between 3 and 6 months postoperatively.

The average length of stay in this study was influenced by the guidelines of local insurance companies. It was significantly longer compared with the lengths of stay allowed by insurance companies in other developed countries. This factor must be taken into account when comparing the average hospital stays with those reported in other series. Most patients were allowed to stand



**Table 3.** Comparison of Complication Rates Among Treatment Groups\*

	Microsurgical Discectomy (n = 344)	Endoscopic Discectomy (n = 230)	Endoscopically Assisted Discectomy (n = 164)	P Value ( $\chi^2$ )	P Value MD-ED ( $\chi^2$ )	P Value ED-EAD ( $\chi^2$ )	P Value MD-EAD ( $\chi^2$ )
Intraoperative							
Dura mater injury	8 (2.33)	7 (3.04)	2 (1.22)	0.46	N/S	N/S	N/S
Nerve root injury	2 (0.58)	2 (0.87)	0 (0)	0.49	N/S	N/S	N/S
Instrument breakage	1 (0.29)	1 (0.43)	0 (0)	0.70	N/S	N/S	N/S
Wrong level	2 (0.58)	2 (0.87)	1 (0.61)	0.49	N/S	N/S	N/S
Conversion	N/A	13 (5.65)	N/A	N/A	N/A	N/A	N/A
Surgical							
Postoperative hematoma	7 (2.03)	4 (1.74)	3 (1.83)	0.95	N/S	N/S	N/S
Infection	5 (1.45)	1 (0.43)	2 (1.22)	0.49	N/S	N/S	N/S
Venous thromboembolism	0 (0)	0 (0)	0 (0)	N/S	N/S	N/S	N/S
Specific							
Spondylodiskitis	1 (0.29)	0 (0)	1 (0.61)	0.53	N/S	N/S	N/S
Transient partial urination disturbance	2 (0.58)	1 (0.43)	1 (0.61)	0.64	N/S	N/S	N/S
Deterioration of neurologic symptoms	12 (3.49)	12 (5.22)	6 (3.66)	0.64	N/S	N/S	N/S
Herniation recurrence	11 (3.20)	16 (6.96)	4 (2.44)	<b>0.03</b>	<b>0.04</b>	0.78	0.06
Segmental instability	20 (5.81)	5 (2.17)	6 (3.66)	0.08	N/S	N/S	N/S

EAD, endoscopically assisted discectomy; ED, endoscopic discectomy; MD, microsurgical discectomy; N/A, not available; N/S, not significant.

\*Bold values indicate statistical significance.

and walk on the second postoperative day and then followed an orthopedic regimen that included avoiding bending, sitting, and lifting weights for 1 month after surgery; only after this initial month were patients allowed to gradually increase activity.

The finding that postoperative instability was more common after MD than after ED may result from additional resection of bone tissue required in several of the MD cases. In these MD cases, marginal excision of lamina, facet joints, and medial facetectomy were occasionally required for adequate nerve root visualization/decompression and for safe removal of herniated disk fragments. Endoscopic assistance in such cases allowed for visualization and removal of migrated fragments without enlarging the surgical approach; consequently, EAD allowed the surgeon to preserve a minimally invasive technique. Patients who required wide decompression were not considered to be good candidates for ED in the retrospective cohort. Therefore, patients were less likely to develop instability after ED because there was no need to perform wide bone decompression in most ED cases. Instead, EDs were performed interlaminarly, with minimal bone resection.

Endoscopic video assistance in cases of technical difficulties had several advantages. Because the image was seen through the

microscope, the full endoscopic image could simultaneously be visualized on the monitor. Thus, EAD enabled the surgeon to visualize the operating field from different angles. It also allowed for visual control of the position of the tip of the instrument, allowing the surgeon to use several instruments simultaneously in a deep wound. In cases of ED, on the other hand, the number of instruments that could be used simultaneously was limited. Moreover, in EAD approaches, there were no shadows of instruments introduced into the operative field, as frequently appear in microscopic lighting. EAD allowed the maintenance of a small interlaminar opening. With EAD, we were able to visualize the nerve root, ventral parts of the dural sac, the lateral recess, and even the disk space itself in greater details before, during, and after the resolution of radicular compression. In several cases, endoscopic assistance allowed for removal of fragments of migrated disk material, which would have been impossible to find without endoscopic visualization.

Some surgeons found ED difficult or even impossible to perform if the disk herniation was centrally localized with the opposite side extension or if the sequester was cranially or caudally displaced.<sup>5,6</sup> For this reason, including difficulties with

hemostasis, we used a standard operative microscope in 4 cases instead of ED. These patients were analyzed in the ED group because they were deemed to have surgical method limitations. EAD was a sound alternative when ED was technically challenging and when MD required an approach extension with violation of facet joints and iatrogenic destabilization of the posterior column.

Disadvantages of EAD included increased operating personnel, additional equipment, and, most importantly, the need for technical proficiency on the part of the surgeon. Special endoscopic surgical skills were an absolute requirement for EAD or ED procedures. All participating neurosurgeons completed certification training in spinal tubular endoscopy and had previous experience with spinal tubular endoscopic procedures before initiation of the study. However, we believe that skills gained within the time of the study indicate a steeper learning curve for endoscopic techniques. This aspect highlights the fact that endoscopic expertise requires a longer period for mastery than might be thought initially.

Although it was not the primary goal of the initial study, we hypothesized that assessment of complication rates may provide valuable information. The power of the study was enough to reveal clinically significant differences in VAS and ODI scores. However, we hypothesized that our study was underpowered to reveal differences in complications. Therefore, we attempted to retrospectively review information on the patients who underwent operations with the same methods for the same indications to assess complications of these operations on more patients and over a longer period. Disk herniation recurrence rates from these data were reherniations within the first 6 months ( $n = 2$  in MD,  $n = 3$  in ED, and  $n = 1$  in EAD groups) and reherniations after 6 months ( $n = 9$  in MD,  $n = 13$  in ED, and  $n = 3$  in EAD groups), which were assessed together and resulted in a higher recurrence rate after ED compared with MD ( $P = 0.04$ ). Even considering early reherniations as an early relapse or failed surgery and excluding them from analysis, there is still a trend toward significance in the recurrence rate between the MD and ED groups ( $P = 0.06$ ). The higher recurrence rate may have been related to the technical difficulty of removing all fragments inside the disk space during ED, a more limited discectomy than that of MD; the inherent nature of the studied endoscopic tubular technique; or the experience of the operative team.

Increases in reherniation after ED compared with MD and technical nuances of ED prompted us to have a stricter selection of candidates for endoscopic operations. We believe that less anatomically complicated and more straightforward cases should be selected for ED because the minimally invasive nature of ED procedures does not outweigh the potential associated increase in herniation recurrence. In all cases in this series, only sequestered and degenerated fragments of the lumbar disk were removed. The necessity of total disk removal is disputable, but we tend to spare discectomy when possible, as do most modern surgeons.<sup>6</sup> A previous study<sup>8</sup> suggests that patients have a higher incidence of recurrent leg and back pain after aggressive discectomy, although these patients had lower rates of herniation recurrence than did patients who underwent limited discectomy.

Differences among the surgical techniques of ED, MD, and EAD have led to the differences in study results. ED involves a transmuscular rather than a subperiosteal route, such as in MD and EAD. The number and type of surgical instruments that can be

simultaneously placed in the operative corridor during ED is limited by 2 working channels, 1 for a suction tube and another for the second instrument, including compatible rongeurs. ED is essentially performed without an assistant. In comparison, MD is performed with an assistant facing the surgeon. Moreover, the number and types of surgical instruments in the operative corridor are not limited in MD. In addition, the surgeon can use a drill, other types of rongeurs, bipolar coagulators, or elevators that would not fit or would not have similar maneuverability in the endoscopic tubular retractor. The tubular retractor of the studied surgical system has a fixed length and may not be convenient to use in obese patients with a deep surgical corridor, and the Caspar retractor used in MD or EAD has a set of petal-like blades of different lengths, enabling depth adjustment. Most importantly, ED and EAD require special endoscopic manual skills and eye–hand coordination and indirect two- or three-dimensional visualization, which substantially differ from skills required for MD. Although the differences in disk herniation extraction may be subtle, in the hands of a spine surgeon who is less familiar with some of these procedures than others, those technical differences may be marked and lead to significant outcome differences. These subtle differences are illustrated by the outcomes found in these surgical groups.

This study provides evidence that minimally invasive endoscopic tubular lumbar discectomy is not superior to the standard MD in terms of 1-year functional outcome within a relatively specific and homogeneous patient population. Moreover, our study shows that minimally invasive ED has a higher risk of disk herniation recurrence than MD and EAD. This finding is important to consider during preoperative consulting with patients and in choosing a method of surgery for an individual case. We believe that ED and MD are not equally suitable for every case of lumbar disk herniation, because of different complication risks. In some patients with thick subcutaneous fat, concomitant spinal stenosis, a centrally located herniation, or disk fragment dislocation, ED is less ideal compared with MD or EAD. Thus, ED, MD, and EAD are all effective and valuable techniques in the armamentarium of spine neurosurgeons and should supplement, rather than replace, each other.

There were several limitations to this study. First, this study was primarily composed of a unique, relatively homogeneous population of railway workers with risky strenuous labor responsibilities. In analyzing the data, we assumed that a patient's absence at long-term follow-up was not related to the surgical or rehabilitation treatment outcome; however, it was probable that this assumption was not accurate because there was a tendency for patients who felt better to avoid the long-term follow-up, whereas patients who felt discomfort were more likely to revisit the hospital and complete the follow-up course. Hence, this potentially skewed and incomplete follow-up data might have exaggerated negative outcomes. We also acknowledge that part of the patient cohort was nonrandomized, although the same inclusion and exclusion criteria were used, which may have an effect on the results obtained.

## CONCLUSIONS

This study compared outcomes of ED, MD, and EAD based on the results of a specific quality-of-life questionnaire, pain-intensity

questionnaire, and complication analysis. Results showed that these 3 surgical techniques are highly effective and have similar 1-year results for quality of life and pain. However, this study indicated that ED is associated with a lower VAS score at discharge but may have a higher risk of disk reherniations than MD. Although this study points to differences in complications resulting from the 3 techniques, larger prospective studies are needed to assess possible surgical differences, complications, and outcomes more firmly. The EAD technique allowed for preservation of a minimally invasive nature of approach and enhanced

visualization of the anatomy that was hidden from view under the microscope.

## ACKNOWLEDGMENTS

The authors are grateful to Andrey V. Egorov, M.D., Andrey A. Kalinin, M.D., and Sergey Yu Panasenkov, M.D., for their supportive contributions to this study, including patient assessments and recruitment. They also thank staff at the Neuroscience Publications office at Barrow Neurological Institute in Phoenix, Arizona, USA, for their kind assistance in the preparation of the article.

## REFERENCES

- Mixer WJ, Barr JS. Rupture of the intervertebral disk with involvement of the spinal canal. *N Engl J Med*. 1934;211:210-215.
- Caspar W. A new surgical procedure for lumbar disc herniation causing less tissue damage through a microsurgical approach. *Adv Neurosurg*. 1977;4:74-80.
- Yasargil MG. Microsurgical operation for herniated disc. *Adv Neurosurg*. 1977;4:81-82.
- Foley KT, Smith MM. Microendoscopic discectomy. *Tech Neurosurg*. 1997;3:301-307.
- Destandau J. [Technical features of endoscopic surgery for lumbar disc herniation: 191 patients]. *Neurochirurgie*. 2004;50:6-10 [in French].
- Arestov SO, Gushcha AO, Kashcheev AA. [Specific features of technique and long-term results of portal endoscopic procedures in lumbosacral disk herniations]. *Zh Vopr Neirokhir Im N N Burdenko*. 2011;75:27-33 [discussion: 33] [in Russian].
- Arts MP, Brand R, van den Akker ME, Koes BW, Bartels RH, Peul WC. Tubular discectomy vs conventional microdiscectomy for sciatica: a randomized controlled trial. *JAMA*. 2009;302:149-158.
- McGirt MJ, Ambrossi GL, Dato G, Sciubba DM, Witham TF, Wolinsky JP, et al. Recurrent disc herniation and long-term back pain after primary lumbar discectomy: review of outcomes reported for limited versus aggressive disc removal. *Neurosurgery*. 2009;64:338-344 [discussion: 344-345].
- Fairbank JC, Couper J, Davies JB, O'Brien JP. The Oswestry low back pain disability questionnaire. *Physiotherapy*. 1980;66:271-273.
- Huskisson EC. Measurement of pain. *Lancet*. 1974;2:1127-1131.
- Glantz SA. *Primer of Biostatistics*. 5th ed. New York, NY: McGraw-Hill; 2001.
- Ostelo RW, Deyo RA, Stratford P, Waddell G, Croft P, Von Korf M, et al. Interpreting change scores for pain and functional status in low back pain: towards international consensus regarding minimal important change. *Spine (Phila Pa 1976)*. 2008;33:90-94.
- Golinvaux NS, Bohl DD, Basques BA, Yacob A, Grauer JN. Comparison of the lumbar disc herniation patients randomized in SPORT to 6,846 discectomy patients from NSQIP: demographics, perioperative variables, and complications correlate well. *Spine J*. 2015;15:685-691.
- Byval'tsev VA, Sorokovikov VA, Egorov AV, Belykh EG, Panasenkov S, Kalinin AA, et al. [Comparative analysis of effectiveness of endoscopic, microsurgical and endoscopic-assisted discectomy in treatment of patients with lumbar intervertebral disk herniations]. *Zh Vopr Neirokhir Im N N Burdenko*. 2010;4:20-26 [discussion: 26] [in Russian].

*Conflict of interest statement: This work was supported by funds from the Russian Science Foundation, Grant number 15-15-30037.*

*Received 4 December 2015; accepted 9 February 2016*

*Citation: World Neurosurg. (2016) 90:273-280.  
http://dx.doi.org/10.1016/j.wneu.2016.02.047*

*Journal homepage: [www.WORLDNEUROSURGERY.org](http://www.WORLDNEUROSURGERY.org)*

*Available online: [www.sciencedirect.com](http://www.sciencedirect.com)*

*1878-8750/\$ - see front matter © 2016 Elsevier Inc. All rights reserved.*

## ***Introducing a NEW section in World Neurosurgery: Doing More with Less***

The Doing More with Less section of *World Neurosurgery* will focus on the particular needs of the lower-resource neurosurgery world, which includes most of the world. The Section solicits submissions of news articles, commentaries, and scientific and technical papers that relate to issues surrounding optimal patient care in resource-challenged environments. In particular, this call for scientific and technical papers focuses on methods for accomplishing neurosurgical goals with low-cost solutions that are practical to implement in neurosurgical operating theaters and care environments where minimal or basic tools and materials are available.